


Nevus Lipomatosus Cutaneous Superficialis Masquerading as Giant Lipoma- A Rare Case Report

PARIDHI¹, SHALINI BAHADUR², MADHUVAN GUPTA³, SHIVANI KALHAN⁴, DEEKSHA SINGH⁵

ABSTRACT

Nevus Lipomatosus Cutaneous Superficialis (NLCS) is an idiopathic, rare skin hamartoma. It occurs due to ectopic deposition of adipocytes in dermis. There are two main clinical forms of NLCS- classic and solitary. Both have different clinical presentations but histologically they show similar morphology characterised by bundles of mature adipocytes in the superficial and deep dermis separated by bundles of collagen. The hallmark of this lesion is absence of connection between subcutaneous fat and adipocyte clusters in dermis. Though NLCS is benign developmental disorder and remains static for a long time, it can be cosmetically unpleasant if it grows to a large size. Herein, authors report a case of a 21-year-old male with a solitary painless pedunculated lump in right thigh for 10 years that clinically presented as giant lipoma due to its soft consistency, cut surface of the mass was yellow and fibrofatty. There was no connection of these adipocytes seen with the subcutaneous fat. Focal collections of adipocytes were also seen around the blood vessels. Sparse perivascular mononuclear inflammatory infiltrate were also noted. Final diagnosis of NLCS was made.

Keywords: Hamartoma, Lipofibroma, Pedunculated lump, Skin

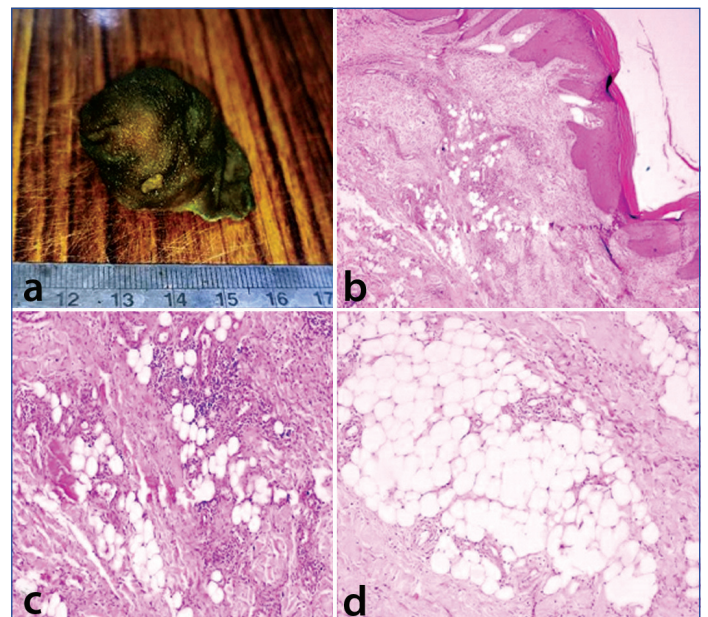
CASE REPORT

A 21-year-old male presented to skin Outpatient Department with complaint of a mass in right thigh for 10 years. The mass was solitary, painless and had increased in size over last 10 years. There was no significant past history. No family history of similar mass was reported. On physical examination, a skin coloured pedunculated mass with soft consistency was seen on posterior aspect of right thigh, measuring approximately 5×4 cm in size. There was no ulceration, excessive hair growth, pigmentation or induration of overlying skin. There were no papules or macules. No cafe-au-lait spots were noted. Systemic examination was within normal limits. Clinical diagnosis of giant lipoma, fibroepithelial polyp or neurofibroma was rendered. An excisional biopsy was done and sent for histopathological examination.

Gross examination revealed single, globular, soft, skin covered pedunculated mass with measuring 5×4×3 cm in size [Table/Fig-1a]. Cut surface of the mass was yellow and fibrofatty. Haematoxylin and Eosin (H&E) stained section showed unremarkable epidermis. Reticular dermis showed adipocytes in small aggregates and scattered singly amongst collagen bundles [Table/Fig-1b]. There was no connection of these adipocytes seen with the subcutaneous fat. Sparse perivascular mononuclear inflammatory infiltrate also noted [Table/Fig-1c]. Focal collections of adipocytes were also seen around the blood vessels [Table/Fig-1d]. A distinct diagnosis of NLCS was rendered. There was no recurrence over six months on follow-up.

DISCUSSION

In 1921, Hoffmann Zurhelle first described NLCS as 'an uncommon cutaneous hamartomatous tumour of skin'. The other name for this lesion is pedunculated lipofibroma [1]. NLCS is a developmental anomaly. Alternatively, it is known as dermolipoma. Though it is commonly presents at birth, it can appear later in life. Occurrence of this rare hamartoma in infants is also known as 'nevus angioliomatousus of Howell' [2]. This disorder is rare and its incidence is unknown. There is no gender, racial, or familial predilection [3]. This lesion is characterised by ectopic accumulation of mature adipocytes in the papillary and/or reticular dermis.



[Table/Fig-1]: a) Globular, soft, skin covered pedunculated mass measuring 5×4×3 cm in size; b) Section showing unremarkable epidermis and small aggregates of adipocytes in reticular dermis among collagen bundles (100X, H&E); c) Section showing sparse perivascular mononuclear inflammatory infiltrate (400X, H&E); d) Focal collections of adipocytes around the blood vessels (400X, H&E).

There are two main clinical variants of NLCS- classic and solitary. The classic variant generally presents at birth or occurs later in life within first two to three decades. It shows zonal or segmental distribution on lower extremities, buttocks or lower back, gluteal region and thigh [4]. Clinically, classic form presents as yellow to skin coloured and consist of multiple papules that coalesce to form plaques with zosteriform, linear or segmental distribution. They are usually slow-growing, with a smooth or cerebriform surface that can enlarge to become giant masses, if left untreated. The largest size reported in the literature is 40×28 cm [5].

Solitary variant of NLCS is characterised by solitary papule or nodule imitating as a skin tag. This type of lesion usually appears in later stages of life, third to sixth decades of life. It has a wide distribution

and can occur at any site, including rare sites like scalp, eyelid, nose and clitoris. However, the histopathological features of both variants are similar [6]. Histopathology of NLCS reveals clusters of ectopic mature adipose tissues along with interspersed collagen bundles in reticular dermis, comprising of 10-50% of the lesion. These mature adipocytes forms small aggregates around blood vessels or eccrine glands, but can also be scattered singly between collagen bundles. These ectopic adipocytes contain large intracytoplasmic lipid vacuoles. No connection is seen between ectopic adipocytes and subcutaneous fat tissue. The epidermis exhibits acanthosis, hyperkeratosis and focal elongation of rete ridges with increased basal pigmentation. Adnexal structures can remain unremarkable or may exhibit focal perifollicular fibrosis.

The index case showed mixed features of both the types making it a rare and difficult diagnosis. The location and age distribution corresponded to the classic type while the gross morphology corresponded to the solitary type.

Pathogenesis of NLCS still remains unclear. However, various theories have been proposed in literature. One theory suggests that degenerative and metaplastic changes in the NLCS occur due to the focal heterotropic developmental displacement of adipose tissue. Another theory proposes that the mature adipocytes grow from mononuclear cells in perivascular area [7].

The individuals at risk and genetic abnormalities associated with this disease are largely unknown. However, some studies mention possible genetic alterations including deletion of the short arm of chromosome 11 and 2p24 [8]. Most of the cases stay at a uniform size but few may continue to increase in size for many years. Occasionally, they may ulcerate due to trauma or ischaemia. Rarely, there may be ulceration with foul smelling discharge, increased number of hair follicles or comedo-like lesions on the surface of the NLCS. Recurrence after excision has been rarely reported [9].

In the patient under discussion, the histological findings were consistent with NLCS and showed more than 10% proliferation of mature adipocytes in the dermis and increased density of collagen bundles. However, the epidermis was predominantly unremarkable [10]. The differential diagnosis of NLCS includes nevus sebaceous, connective tissue nevus, neurofibroma, lymphangioma, haemangioma, Goltz syndrome (focal dermal hypoplasia) and skin appendageal tumours like trichoepitheliomas and cyclindromas. Similar dermal collections of adipocytes are also seen in some melanocytic nevi, pedunculated lipofibromas and Goltz syndrome. However, in Goltz syndrome, in addition to the cluster of adipocytes in dermis, there is extensive attenuation of collagen with atrophic dermis and skin appendages. Histopathology plays an important role in differentiating these lesions from each other. Hence, a biopsy is recommended for confirmation of diagnosis [7].

The NLCS is a cosmetic defect. There are no known systemic complications and it is not a premalignant condition. In literature, rarely NLCS is found to be associated with folliculosebaceous cystic hamartoma, deep penetrating nevus or lipomas. Early recognition of this lesion enables conservative resection, thereby avoiding extensive reconstruction of the defect. There are differences in the approach to treatment among clinicians with respect to NLCS. Few believe no treatment is necessary in most cases. However, sometimes the mass enlarges to a big size, if left untreated. Surgical excision is a simple and adequate treatment for all these lesions. Carbon dioxide laser has recently been reported to be a useful method of treatment for NLCS, especially in the multiple types [11].

CONCLUSION(S)

The NLCS is a benign developmental disorder that can remain static for life. This case highlights its rarity and importance of early diagnosis and treatment as the lesion can grow to large size that may raise the cosmetic concerns for the patient. A long term follow-up is required to rule out recurrence and occurrence of similar lesions elsewhere in the body.

REFERENCES

- Patil SB, Narchal S, Paricharak M, More S. Nevus lipomatosus cutaneous superficialis: A rare case report. *Iran J Med Sci.* 2014;39(3):304-07. PMID: 24850990; PMCID: PMC4027012.
- Jain A, Sharma A, Sharda R, Aggarwal C. Nevus lipomatosus cutaneous superficialis: A rare hamartoma. *Indian J Surg Oncol.* 2020;11(1):147-49. <https://doi.org/10.1007/s13193-019-00997-4>.
- Baltaci D, Akyazi H, Mungan S, Kara IH. Nevus lipomatosus cutaneous superficialis: Case report. *J Clin Exp Invest.* 2011;2(4):457-59. <https://doi.org/10.5799/ahinjs.01.2011.04.0096>.
- Goyal M, Wankhade VH, Mukhi JI, Singh RP. Nevus lipomatosus cutaneous superficialis- A rare hamartoma: Report of two cases. *J Clin Diagn Res.* 2016;10(10):WD01-WD02. Doi: 10.7860/JCDR/2016/19126.8595. Epub 2016 Oct 1. PMID: 27891437; PMCID: PMC5121775.
- Alotaibi H, Alsaif F, Alali A, Almashali M, Al-Dabeeb D, Altaweel AA. Nevus lipomatosus cutaneous superficialis: A single-center case series of 5 patients. *Case Rep Dermatol.* 2018;10(2):138-44. Doi: 10.1159/000488900. PMID: 29928203; PMCID: PMC6006638.
- Goucha S, Khaled A, Zéglalou F, Rammeh S, Zermani R, Fazaia B. Nevus lipomatosus cutaneous superficialis: Report of eight cases. *Dermatol Ther (Heidelb).* 2011;1(2):25-30. Doi: 10.1007/s13555-011-0006-y. Epub 2011 Sep 9. PMID: 22984661; PMCID: PMC3437641.
- Lima CDS, Issa MCA, Souza MB, Góes HFO, Santos TBPD, Vilar EAG. Nevus lipomatosus cutaneous superficialis. *An Bras Dermatol.* 2017;92(5):711-13. Doi: 10.1590/abd1806-4841.20175217. PMID: 29166514; PMCID: PMC5682701.
- Cardot-Leccia N, Italiano A, Monteil MC, Basc E, Perrin C, Pedeutour F. Naevus lipomatosus superficialis: A case report with a 2p24 deletion. *Br J Dermatol.* 2007;156(2):380-81. Doi: 10.1111/j.1365-2133.2006.07622.x. PMID: 17223884.
- Dhamija A, Meherda A, D'Souza P, Meena RS. Nevus lipomatosus cutaneous superficialis: An unusual presentation. *Indian Dermatol Online J.* 2012;3(3):196-98. Doi: 10.4103/2229-5178.101819. PMID: 23189254; PMCID: PMC3505429.
- Ghosh SK, Bandyopadhyay D, Jamadar NS. Nevus lipomatosus cutaneous superficialis: An unusual presentation. *Dermatol Online J.* 2010;16(7):12. <http://dx.doi.org/10.5070/D330v6h4j4>.
- Kim YJ, Choi JH, Kim H, Nam SH, Choi YW. Recurrence of nevus lipomatosus cutaneous superficialis after CO(2) laser treatment. *Arch Plast Surg.* 2012;39(6):671-73. Doi: 10.5999/aps.2012.39.6.671. Epub 2012 Nov 14. PMID: 23233898; PMCID: PMC3518016.

PARTICULARS OF CONTRIBUTORS:

- Senior Resident, Department of Pathology, Government Institute of Medical Sciences, Greater Noida, Uttar Pradesh, India.
- Professor, Department of Pathology, Government Institute of Medical Sciences, Greater Noida, Uttar Pradesh, India.
- Senior Resident, Department of Pathology, Government Institute of Medical Sciences, Greater Noida, Uttar Pradesh, India.
- Professor and Head, Department of Pathology, Government Institute of Medical Sciences, Greater Noida, Uttar Pradesh, India.
- Senior Resident, Department of Pathology, Government Institute of Medical Sciences, Greater Noida, Uttar Pradesh, India.

NAME, ADDRESS, E-MAIL ID OF THE CORRESPONDING AUTHOR:

Madhuvan Gupta,
Senior Resident, Department of Pathology, Government Institute of Medical Sciences,
Greater Noida, Uttar Pradesh, India.
E-mail: drmadhuvangupta@gmail.com

AUTHOR DECLARATION:

- Financial or Other Competing Interests: None
- Was informed consent obtained from the subjects involved in the study? NA
- For any images presented appropriate consent has been obtained from the subjects. NA

PLAGIARISM CHECKING METHODS: [Jain H et al.]

- Plagiarism X-checker: Dec 12, 2022
- Manual Googling: Jan 04, 2023
- iThenticate Software: Jan 16, 2023 (15%)

ETYMOLOGY: Author Origin

Date of Submission: **Nov 10, 2022**
Date of Peer Review: **Jan 06, 2023**
Date of Acceptance: **Jan 18, 2023**
Date of Publishing: **Apr 01, 2023**